

## Restoration of saphenous–femoral junction competence with Venocuff® in 1-day surgery

G. Quarto \*, M. Santoro, C. de Werra, G. Raimondi, G. Benassai, P. Forestieri

*Department of General Surgery, Faculty of Medicine, 'Federico II' University, Naples, Italy*

### Abstract

The treatment of sapheno-femoral junction (SFJ) reflux represents the first step in an effective therapeutic program for varicose veins disease. SFJ valvuloplasty restores valve function by reducing vein wall dilatation at the valve annulus. The Venocuff® system makes it possible to band SFJ easily and safely. We used it in 10 cases with no early or late operating complications. Satisfactory SFJ competence has been achieved with aesthetic and functional improvement. © 1997 Elsevier Science Ireland Ltd.

*Keywords:* Sapheno-femoral reflux; Valvuloplasty; Venocuff®

### 1. Introduction

About 80% of patients suffering from varices of the long saphenous vein present some degree of reflux at the sapheno-femoral junction (SFJ) which is well detected by doppler CW and duplex sonography [1]. Therefore, the treatment of this reflux represents the first step of every therapeutic program, either ablative (short or long stripping) or conservative (CHIVA), for this pathology [2]. Histological observations show that sapheno-femoral reflux in early varicose vein syndrome is due to a separation of valve cusps in a dilated sclerotic vein wall. SFJ external valvuloplasty restores valve function by reducing vein wall dilatation [3,4]. In order to perform it, we used the Venocuff® system. This is a Dacron-strengthened silicon cuff which is placed around the vein at the site of the valve, to reduce incompetence and to bring the valve cusps into apposition [5].

### 2. Patients and methods

Patients were selected through accurate anamnesis and clinical examination, routine laboratory assessment

(including AT III and fibrinogenemia dosage), doppler CW and duplex sonography. Inclusion criteria were: primary and early venous insufficiency; sapheno-femoral reflux not below the thigh; age under 45 years old; initial stage of venous discomfort with early varices and absence of cutaneous dyschromia; sonographic evidence of normal valve cusps (pre- and/or intra-operative). Exclusion criteria were: clinical history of superficial and/or deep thrombophlebitis (endothelial damage and increased thrombotic risk); previous or recent sclerotherapy (endothelial damage and increased thrombotic risk); congenital valve absence, abnormal valvular cusps; wide enlargement of the long saphenous vein; SF ostium diameter over 11 mm; local and/or general contra-indications to surgery (particularly inguinal dermatitis). In our Department, from January 1995 to the present, 10 women with a median age of 28 years (range 19–42) have been operated on. All the patients were subjected to 'short-term' antibiotic prophylaxis (teicoplanine plus third-generation cephalosporine) and all the operations were performed under local anesthesia and as 1-day surgery cases. Through an inferior transverse inguinal approach (3 cm), the SFJ was dissected, as in a conventional saphenous ligation. All collateral veins of the terminal saphenous vein were tied and dissected. Terminal and subterminal valves were localized by inspection and

\* Corresponding author.

intra-operative ultrasonography. Venocuff<sup>®</sup> was placed around the valvular site [4] (Fig. 1). Restoration of SFJ patency and competence were assessed qualitatively by following the 'milking technique'. We occluded the saphenous vein 3 cm proximally to Venocuff<sup>®</sup> using a vessel loop. The proximal segment was then emptied by 'milking' blood into the distal segment. If this maneuver is found to be possible and easy, patency is assessed. Every filling of the proximal segment, spontaneously and/or elicited by Valsalva, and/or compressive maneuvers, represents blood reflux through the valve. To confirm these clinical data, we performed an intra-operative duplex Doppler scanning, using the Valsalva and/or compressive maneuvers. These clinical and instrumental evaluations were useful in detecting residual reflux and saphenous vein patency, making it possible to perform correction by valvuloplasty or, eventually, conventional surgery. In the last two cases we used intra-operative angioscopy, through the largest tributary vein. This examination confirmed the presence of a complete apparatus of terminal and subterminal saphenous valves, making it possible to more accurately calibrate the valvuloplasty. Finally, an elastic bandage was used for 9 days, postoperatively followed by a compression stocking for 30 days according to the degree of deep venous insufficiency.

### 3. Results and conclusions

There were no early or late operating complications and return to normal work and life activity occurred 2–4 days after the operation without any antithrombotic prophylaxis. A mean follow-up of 5.8 months (range 1–15) was carried out by monthly clinical examination, CW doppler and duplex sonography (Fig. 2). We found no pathological signs with normal SFJ competence and patency. Eight patients declared a complete

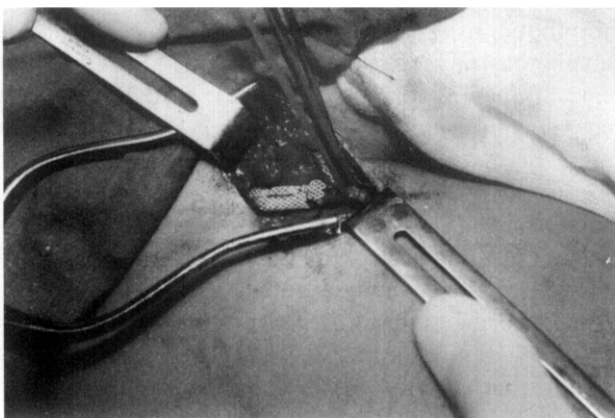


Fig. 1. Venocuff positioned around terminal sapheno-femoral vein in correspondence of the valvular site.

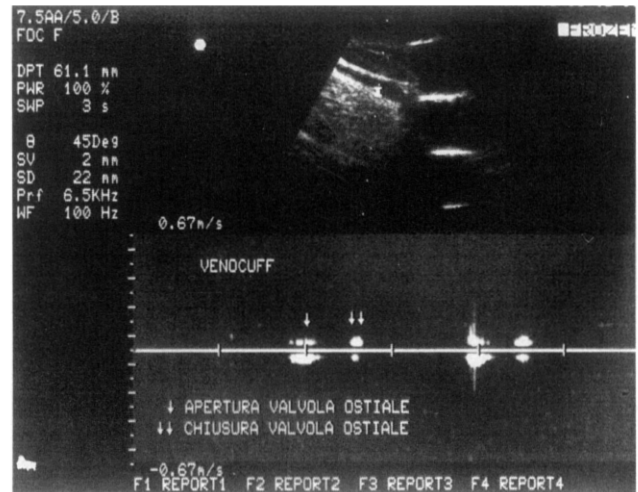


Fig. 2. Duplex sonography after Venocuff application: demonstration of the valvular lock (↓ opening and ↓↓ closure of valvular ostium).

remission of symptomatology (nocturnal cramps, swelling and heavy legs) with satisfactory aesthetic and functional improvement. Two patients with a medium degree of deep venous insufficiency had persistent symptoms of heavy legs, with, however, a significant reduction compared with the preoperative situation. In conclusion, external SFJ valvuloplasty seems capable of restoring continence of the superficial venous system by treating one of the causes of chronic venous insufficiency—vein wall dilatation at the valve annulus. An adequate follow-up is necessary to assess long-term results. If this technique makes it possible to preserve and/or restore normal hemodynamics in the long saphenous vein (LSV), it will be a great medical goal. In fact, LSV is still the most successful graft available for arterial, cardiac and venous by-pass [6].

### References

- [1] Quarto G, Turco N, Mozzillo N et al. Le varici degli arti inferiori: quale la scelta terapeutica? *Angiologia* '86. Bologna: Monduzzi Editore, 1986:1023–1026.
- [2] Quarto G, Turco N, Formato A et al. Trattamento ambulatoriale delle varici degli arti inferiori. Atti 7° Congresso Nazionale S.I.F.C.S., Firenze, Italia, 10–12 Dicembre 1990. Bologna: Monduzzi Editore, 1990:319–322.
- [3] Corcos L, Peruzzi GP. Valvuloplastie externe de la junction saphéno-fémorale. *Phlebologie* 1991; 2:497–508.
- [4] Zamboni P, Fasbarro V, Pozza E et al. External valvuloplasty of the sapheno-femoral junction and tributaries preservation. In: Raymond-Martinbeau P, Prescott R, Zummo M. eds. *Phlébologie* 92. Paris: John Libbey Eurotext, 1992:1252–1254.
- [5] Guarnera G, Furgiuele S, Camilli S. The role of external banding valvuloplasty with the venocuff in the treatment of primary deep venous insufficiency. *Phlebology* 1994; 9:150–153.
- [6] Bihari I. Saving the greater saphenous vein for prothesis, with incomplete ligation, in varicose cases. In: Davy A, Stemmer R. eds. *Phlébologie* 1989. Paris: John Libbey Eurotext, 1989:1018–1020.